


# Italian Literature Watch



**Aprile 2010**

## Annals of Thoracic Surgery




[Minimally invasive heart-port assisted technique as standard first choice approach for left ventricle endoplasty: a ten-year single-center experience.](#)

Totaro P, Alloni A, Cattadori B, Monterosso C, Degani A, Maurelli M, D'Armini AM, Vigano M.  
Ann Thorac Surg. 2010  
Apr;89(4):1200-3.

[Management of percutaneous aortic valve malposition with a transapical "valve-in-valve" technique.](#)

Stabile E, Sorropago G, Cota L, Cioppa A, Agrusta M, Lucchetti V, Rubino P.  
Ann Thorac Surg. 2010  
Apr;89(4):e19-21.

## European Journal of Cardiothoracic Surgery



### [Off-pump coronary artery bypass surgery versus standard linear or pulsatile cardiopulmonary bypass: endothelial activation and inflammatory response.](#)

Onorati F, Rubino AS, Nucera S, Foti D, Sica V, Santini F, Gulletta E, Renzulli A.  
Eur J  
Cardiothorac  
Surg. 2010  
Apr;37(4):897-904. Epub  
2009 Dec 16.

### [Port-access surgery as elective approach for mitral valve operation in re-do procedures.](#)

Ricci D, Pellegrini C, Aiello M, Alloni A, Cattadori B, D'Armini AM, Rinaldi M, Viganò M.  
Eur J  
Cardiothorac  
Surg. 2010  
Apr;37(4):920-5. Epub 2009  
Nov 25.

### [Daily reoxygenation decreases myocardial injury and improves post-ischaemic recovery after chronic hypoxia.](#)

Milano G, Corno AF, Samaja M, Morel S, Vassalli G, von Segesser LK.  
Eur J  
Cardiothorac  
Surg. 2010  
Apr;37(4):942-9. Epub 2009  
Dec 6

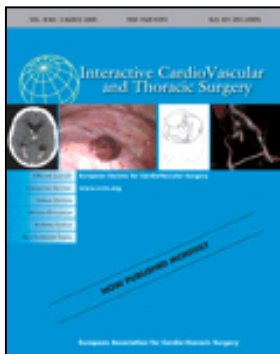
### [A left atrial ablation with bipolar irrigated radio-frequency for atrial fibrillation during minimally invasive mitral valve surgery.](#)

Solinas M, Bevilacqua S, Karimov JH, Glauber M.  
Eur J  
Cardiothorac  
Surg. 2010  
Apr;37(4):965-  
6. Epub 2009  
Nov 25.

[Femoro-axillary cardiopulmonary bypass for giant abdominal aortic aneurysm repair prior to staged cardiac operation for ischaemic cardiomyopathy.](#)

Pocar M, Moneta A, Passolunghi D, Donatelli F.  
Eur J  
Cardiothorac  
Surg. 2010  
Apr;37(4):972-  
4. Epub 2009  
Oct 22.

### **Interactive Cardiovascular and Thoracic Surgery**



[Surgical ventricular reconstruction with different myocardial protection strategies. A propensity matched analysis.](#)

D'Onofrio A, Cugola D, Bolgan I, Menicanti L, Fabbri A, Di Donato M.  
Interact Cardiovasc Thorac  
Surg. 2010 Apr;10(4):530-4.  
Epub 2010 Jan 13.

[Valve repair in congenital aortic valve abnormalities.](#)

Pozzi M, Quarti A, Colaneri M, Oggianu A, Baldinelli A, Colonna PL.  
Interact Cardiovasc Thorac  
Surg. 2010 Apr;10(4):587-91.  
Epub 2010 Jan 14.

[Argatroban as a substitute of heparin during cardiopulmonary bypass: a safe alternative?](#)

Follis F, Filippone G, Montalbano G, Floriano M, Lobianco E,

D'Ancona G, Follis M.  
Interact Cardiovasc Thorac  
Surg. 2010 Apr;10(4):592-6.  
Epub 2010 Jan 8.

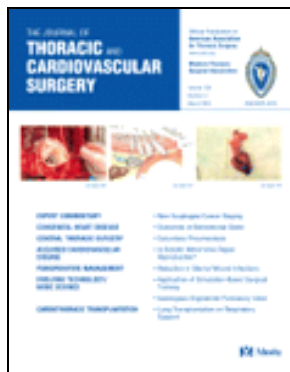[Endovascular graft deployment in the false lumen of type B dissection.](#)

Follis F, Filippone G, Stabile A, Montalbano G, Floriano M, Finazzo M,  
Follis M.  
Interact Cardiovasc Thorac  
Surg. 2010 Apr;10(4):597-  
9. Epub 2010 Jan 29.

[Coronary graft use of a new external mesh support.](#)

Rescigno G, Angelini A, D'Alfonso A, Torracca L.  
Interact Cardiovasc Thorac  
Surg. 2010 Apr;10(4):645-7.  
Epub 2010 Jan 29.

**The Journal of Thoracic and Cardiovascular Surgery**



[Moderate chronic kidney disease and left ventricular hypertrophy after aortic valve replacement for aortic valve stenosis.](#)

Benedetto U, Melina G, Angeloni E, Refice S, Scafani G, Roscitano A,  
Tonelli E, Sinatra R.  
J Thorac Cardiovasc Surg.  
2010 Apr;139(4):881-6.

[Predictive value of the National Institutes of Health Stroke Scale and the Mini-Mental State Examination for neurologic outcome after coronary artery bypass graft surgery.](#)

Nussmeier NA, Miao Y, Roach GW, Wolman RL, Mora-Mangano C,  
Fox M, Szekely A, Tommasino C, Schwann NM, Mangano DT;  
Ischemia and Education Foundation and the Multicenter Study of  
Perioperative Ischemia Research Group.

[Repair of postdissection descending thoracic aneurysm with right-sided aortic arch and aberrant left subclavian artery.](#)

Follis F, Filippone G, Montalbano G, LoBianco E, Finazzo M, Follis M.  
J Thorac Cardiovasc Surg.  
2010 Apr;139(4):1086-7.  
Epub 2009 Nov 11. No  
abstract available.